

A CASE REPORT

HYDROURETERONEPHROSIS CAUSED BY A RETROCAVAL URETER A RARE CASE REPORT

Nadeem Bin Nusrat¹, Assad ur Rehman², Nauman Zafar³, Shujah

Muhammad⁴, Sarmad Imtiaz Bajwa⁵, Saira Imtiaz⁶

^{1,2,3,4,5,6} *Department of Urology, Pakistan Kidney and liver institute and Research Centre Lahore*

ABSTRACT

Background: An abnormality of the inferior vena cava the retrocaval ureter is an uncommon congenital disorder. In development, the ureter descends posteriorly to the inferior vena cava. Although it commonly affects patients in their paediatric years, people aged in their third and fourth decades of life have the highest likelihood to express symptoms like hydronephrosis, which is usually, in the end, caused by a ureteric blockage. Also, retrocaval ureters may have no symptoms at all, which may explain why they're not frequently found globally or reported less widely. In this case, the male patient's medical record was surveyed by us, and the resulting findings showed that a 21-year-old had a right-sided UPCO due to a right retrocaval ureter for the Ages. The double J stent was placed, and this problem was treated clinically with a right pyeloplasty.

INTRODUCTION

The circumcaval ureter, also called the retrocaval ureter, has been identified in less than 200 cases since it was first described in 1893 [1]. The proximal ureter inserts posteriorly into the renal pelvis and then into the inferior vena cava (IVC) as a result of this abnormality. The infrarenal IVC forms abnormally, ventrally of the sub cardinal vein and, hence, ventrally of the ureter, from the vitalize vein suprarenal part (Figure 1). Typically, the infrarenal IVC is formed dorsally from the supracardinal vein between fetal weeks four through eight [1]. The distal ureter commonly traverses superficially over the common iliac arteries before reaching the bladder [2]. Despite the fact that the abnormality is present from birth, some patients with IVC compression of their proximal ureter, resulting in hydronephrosis or hydroureteronephrosis, occasionally exhibit no symptoms until their third or fourth decade [3].

Keywords: Retrocaval ureter, Hydroureteronephrosis, Ureteral obstruction, Congenital anomaly, Pyeloplasty, Double J stent.

How to Cite: Bin Nusrat N, ur Rehman A, Zafar N, Muhammad S, Imtiaz Bajwa S, Imtiaz S. Hydroureteronephrosis Caused by a Retrocaval Ureter: A Rare Case Report. *Pakistan J Urol*. 2023;1(01):28-32. [doi:10.69885/pju.v1i01.19](https://doi.org/10.69885/pju.v1i01.19).

Corresponding Author: Saira Imtiaz

Department of Urology, Pakistan Kidney and liver institute and research Centre Lahore

Email saira.khan@pkli.org.pk

<https://orcid.org/0000-0003-1197-7565>

Cell no: +92 336 9514178

Article History

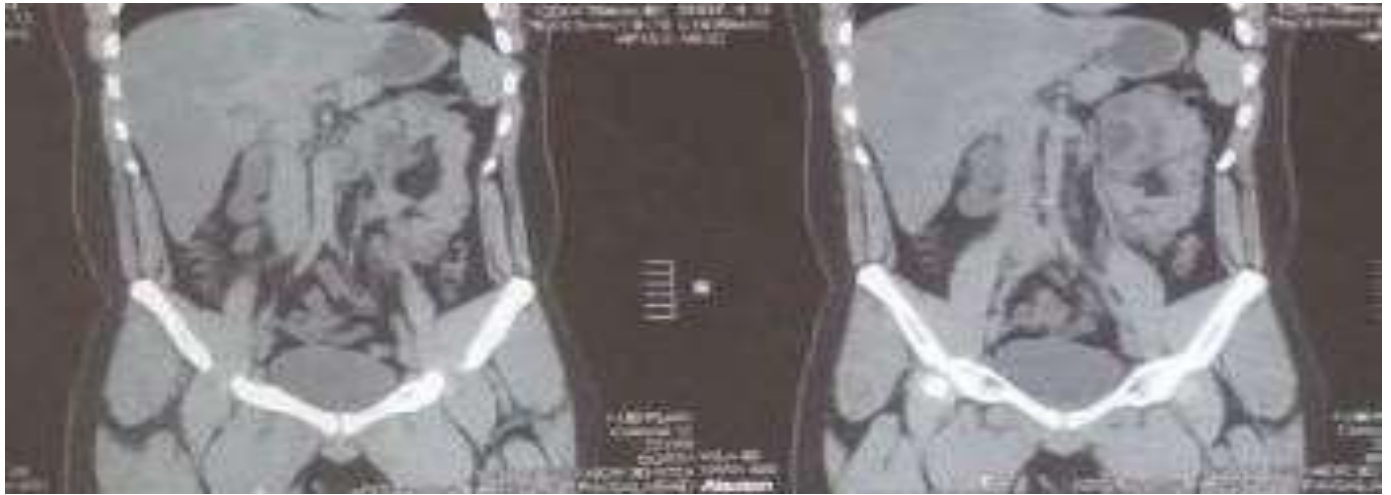
Received:	January	14-2023
Revision:	February	27-2023
Accepted:	April	16-2023
Published:	July	05- 2023

HYDROURETERONEPHROSIS CAUSED

CASE PRESENTATION

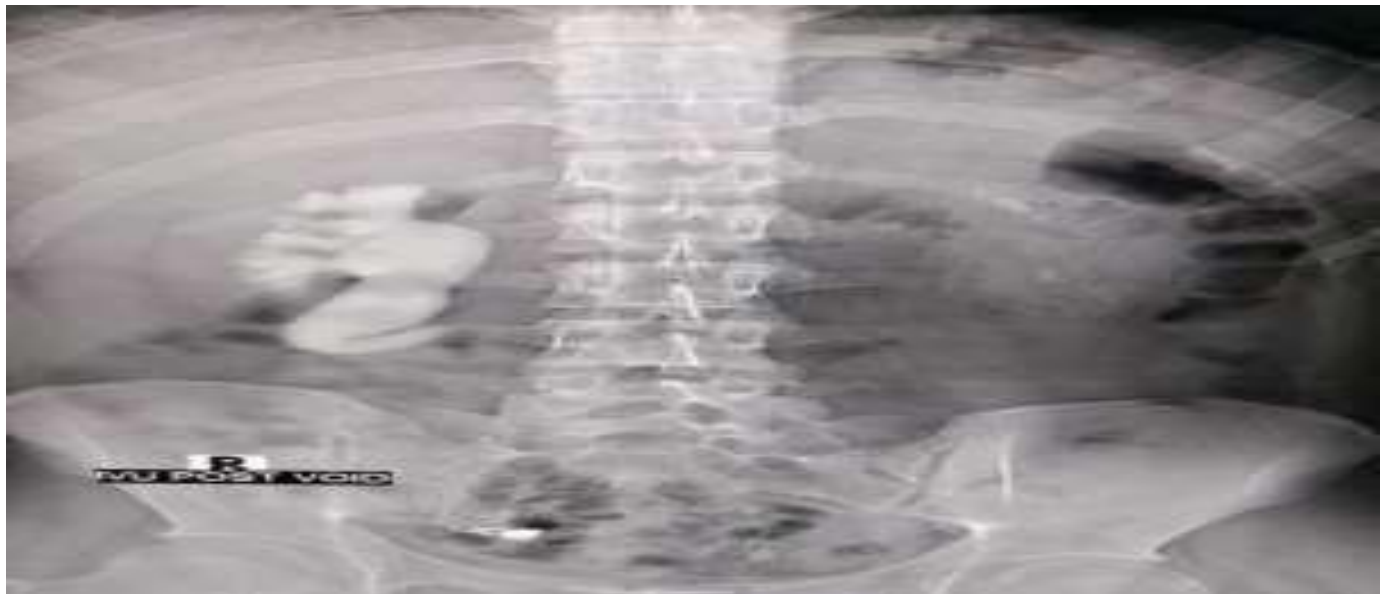
The male patient in this instance, who was 21 years old, was seen in the urology outpatient department. He had been experiencing right flank pain for a month but had no fever, hypertension, diabetes, or myelitis. His primary diagnosis was chronic obstructive yelonephritis. A year ago, he underwent a surgical procedure for stone passage. A retrocaval ureter with kinking at the level of the L-4 vertebra, along with an upstream hydro ureter and hydronephrosis, was observed on the right side of the abdomen and pelvis on computed tomography (CT) scans (Figure 1).

Figure 1: Coronal computed tomography of the abdomen and pelvis showing a visible intravenous contrast-dilated ureter flowing beneath the inferior vena cava. (Fish-hook sign)



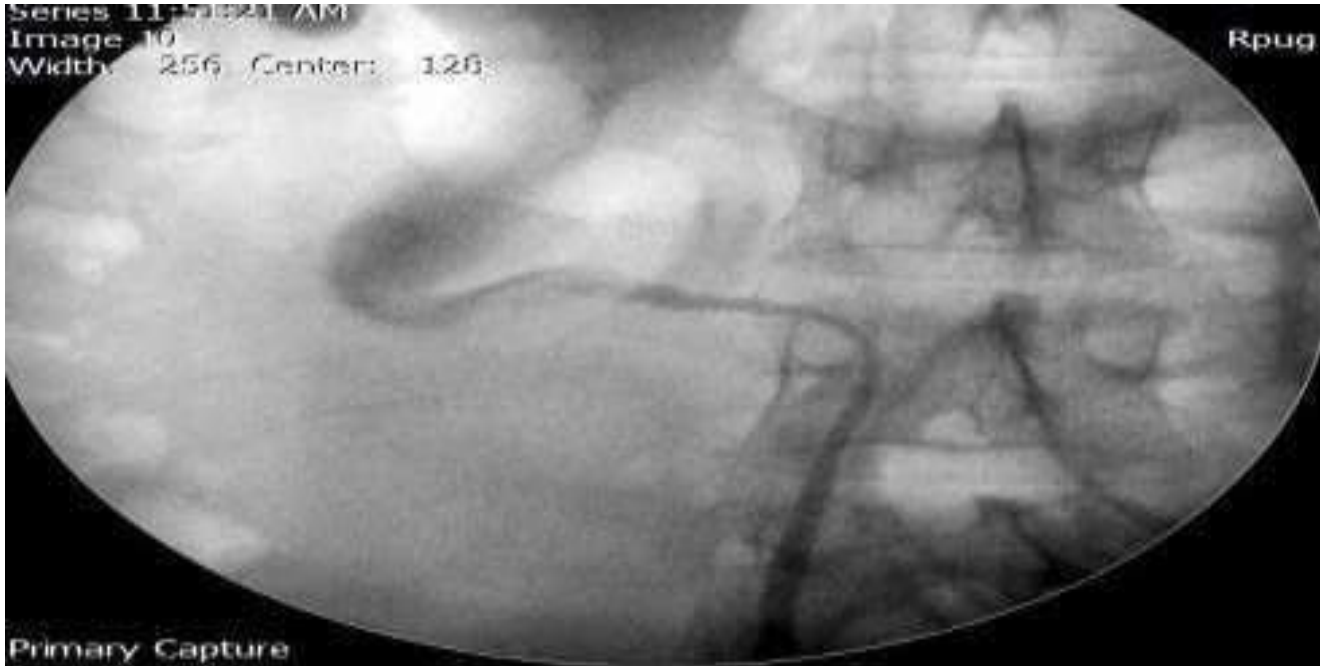
The patient had retrocaval ureter-related moderate hydronephrosis, although he showed no symptoms for a few years. But he came with right flank pain for one month. A renal scan showed adequate functioning of the left kidney was seen with no outflow obstruction, whereas the properly functioning right-Sided kidney with sluggish clearance in response to diuretic stress (Figure 2).

Figure 2: Diuretic renogram showing mild obstruction Intravenous urogram (IVU) was also done to confirm dilated ureter was coursing behind IVC, showing a Fish-hook sign.



HYDROURETERONEPHROSIS CAUSED

Figure 3: Intravenous urogram (IVU) showing Fish-hook shaped deformity



INVESTIGATIONS

Complete blood count (CBC), chemistry panel (CMP), liver, and renal function tests performed before surgery on the patient were generally unremarkable. However, table no. 1, in this case, presents some results from a renal scan.

Investigations	Values	Normal Range
Total GFR (Both Kidneys)	88 ml/min	90-120 ml/min
Left Kidney GFR	48 ml/min	60 or above ml/min
Right Kidney GFR	40 ml/min	60 or above ml/min
Differential function of Left Kidney	55%	Between 45% and 55%
Differential Role of Right Kidney	45%	Between 45% and 55%

MANAGEMENT

A retrograde uteropyelogram (RPUG) was done before pyeloplasty for further confirmation that showed the right ureter passing posterior to the inferior vena cava (retrocaval ureter) shown in Figure 4. Therefore, he was clinically managed for right Pelviureteric junction obstruction (PUJO) due to right retrocaval ureter via right pyeloplasty and double J stent for better management.

DISCUSSION

Type one and type two retrocaval ureters can be separated into two groups. In type 1, the third lumbar vertebra is the level at which the ureter attaches posteriorly to the IVC—an S- or fish-hook-shaped malformation results from the moderate-to-severe hydronephrosis that causes it. In type two, which is less frequent, the proximal ureter travels posteriorly to the IVC at the same level as the renal pelvis when it takes on a smooth sickle-shaped curvature [3-5]. Urine flow may be restricted as a result of ureteric, renal pelvic, and renal calyces enlargement. Severe circumstances may result in renal cortical atrophy [6]. The patient in our instance had a retrocaval ureter of type 1. Symptoms of obstructive uropathy include nephrolithiasis, recurrent UTIs, and soreness in the Right flank., and hematuria are commonly used to define the clinical look of symptomatic patients [7]. Chronic flank pain, typical laboratory results, as well as right-sided hydronephrosis found during CT: these are the medical characteristics of both patients from three previous reports. An indication of the severity of the hydronephrosis is not given, but excision of the retrocaval segment and end-to-end ureteral anastomosis were recommended in both case reports. The patient got a right pelvic ureteral-junction "blockage"(PUJO) this time, & had right flank pain. Retrocaval ureter can be diagnosed by imaging in several ways. CT urography is the preferred method since it is the most accurate and least evasive way of interpreting the 8] retrocavali ureter. Graphically, it shows the relationships between IVC and the ureter. A spiral CT scan can define the ureter and IVC, which, according to some reports, is better. No radiation risk or iodine damage is suffered by CT imaging and magnetic resonance imaging [9]. A renal nuclear scan can determine the extent of blockage. An ultrasound can show a kidney's pyelo-calyceal dilatation. In our instance, an intravenous urogram (IVU), a retrograde pyelogram, and computed tomography of the kidneys, ureters, and bladder (KUB) were used to diagnose a retrocaval ureter. Surgery is necessary for patients who are symptomatic and have severe hydronephrosis and failing kidney function. Still, it is not required for individuals who are asymptomatic and have mild to moderate hydronephrosis. [10]. In our situation, the patient had hydroureteronephrosis symptoms brought on by a retrocaval ureter. Hydronephrosis can be graded in a variety of ways. The severity of renal pelvic dilatation is evaluated by the Society of Foetal Urology (SFU) as opposed to parenchymal loss, assessed by the radiology grading system. Although the most widely used, SFU is mainly employed to evaluate neonatal and

infant pelvicalyectasis. By considering the renal parenchyma's quality and the dilatation of the pelvicalyceal system, the Onen grading method assesses renal impairment. The characteristics of this grading scheme are repeatable and standardized [11].

CONCLUSIONS

a retrocaval ureter observed on a CT scan has caused a rare type of clinically symptomatic hydronephrosis. Utilizing a CT scan represents the most effective preoperative diagnostic method. Asymptomatic patients should undergo conservative treatment, although minimally invasive laparoscopic surgery is the standard of care for rectifying this abnormality. While retrocaval ureter is a rare anomaly, more cases are regularly reported. The root cause of this is likely multifaceted, possibly involving advancements in radiographic imaging, improved healthcare access, or an increase in physician reports. Nonetheless, whether there is a low or high index of suspicion for this condition, it is crucial to consider the retrocaval ureter in patients with symptomatic hydronephrosis.

Disclaimer: Nil

Conflict of Interest: Nil

Funding Disclosure: Nil

Authors Contribution

Concept & Design of Study: Nadeem Bin Nusrat¹

Drafting: Assad ur Rehman², Nauman Zafar³

Data Analysis: Shujah Muhammad⁴

Critical Review: Sarmad Imtiaz Bajwa⁵, Saira Imtiaz⁶

Final version: All authors have reviewed and approved the final manuscript..

REFERENCES

1. Atawurah H, Maison PO, Owusu-Ansah M, Asante-Asamani A: Retrocaval ureter: report of two cases. *Case Rep Urol*. 2019, 2019:2815748. 10.1155/2019/2815748
2. Lesma A, Bocciardi A, Rigatti P: Circumcaval ureter: embryology. *Eur Urol Suppl*. 2006, 5:444-8. 10.1016/j.eursup.2016.02.008
3. Kyei MY, Yeboah ED, Klufio GO, et al.: Retrocaval ureter: two case reports. *Ghana Med J*. 2011, 45:177-80.

HYDROURETERONEPHROSIS CAUSED

4. Ray DN, Smith NF, Quiros J, Thachettu C, McKenzie W. An incidental finding of retrocaval ureter causing hydroureteronephrosis. *Cureus*. 2022 Sep 9;14(9).
5. Iqbal S, Raiz I, Faiz I: Bilateral hydroureteronephrosis with a hypertrophied, trabeculated urinary bladder. *Malays J Med Sci*. 2017, 24:106-15. 10.21315/mjms2017.24.2.14
6. De Arruda GJ, de Arruda Neto JF, Eroles JC, Spessoto LC, de Arruda JG, Fácio FN Jr: Incidental finding of the retrocaval ureter in a patient without hydronephrosis. *AME Case Rep*2018,2:42. 10.21037/acr.2018.09.01
7. Abdessater M, El Khoury R, Elias S, Bart S, Coloby P, Sleiman W: Diagnosis and laparoscopic management of retrocaval ureter: a review of the literature and our case series. *Int J Surg Case Rep*. 2019, 59:165-75. 10.1016/j.ijscr.2019.05.036
8. Igbokwe MC, Ojah OA, Kamba U, Adetunbi AR, Onyebuchi AN, Onwuansoanya UE. Diagnostic dilemma and surgical management of circumcaval ureter: A case report. *Journal of West African College of Surgeons*. 2023 Oct 1;13(4):123-6.
9. Matsuda T, Yasumoto R, Tsujino T: Laparoscopic treatment of a retrocaval ureter. *Eur Urol*. 2019,29:115-8. 10.1159/000473729
10. Onen A: Grading of hydronephrosis: an ongoing challenge. *Front Pediatr*. 2020, 8:458. 10.3389/fped.2020.00458



Open Access This article is licensed under a Creative Commons Attribution 4.0 International License, which permits use, sharing, adaptation, distribution and reproduction in any medium or format, as long as you give appropriate credit to the original author(s) and the source, provide a link to the Creative Commons license, and indicate if changes were made. The images or other third-party material in this article are included in the article's Creative Commons license unless stated otherwise in a credit line to the material. Suppose the material is not included in the article's Creative Commons license, and your intended use is not permitted by statutory regulation or exceeds the permitted use. In that case, you will need to obtain permission directly from the copyright holder. To view a copy of this license, visit: <http://creativecommons.org/licenses/by/4.0/>. **The Author(s) 2023**