

**CASE-REPORT****Pak J Urology 2023;  
1 (6): 24-28****Hydroureteronephrosis Caused by a Retrocaval Ureter, A Rare Case Report**Nadeem Bin Nusrat<sup>1</sup>, Assad ur Rehman<sup>2</sup>, Nauman Zafar<sup>3</sup>,Shujah Muhammad<sup>4</sup>, Sarmad Imtiaz Bajwa<sup>5</sup>, Saira Imtiaz<sup>6</sup>,<sup>1,2,3,4</sup> Constant Urologist Department of Urology, Pakistan Kidney and liver institute and research center Lahore<sup>5</sup> Senior Register Department of Urology, Pakistan Kidney and liver institute and research center Lahore<sup>6</sup> Research Associate Department of Urology, Pakistan Kidney and liver institute and research center Lahore**Article History**  
Received: April 11, 2023  
Accepted: Sep 28, 2023  
Revised: October 12, 2023  
Online: October 18, 2023Corresponding Author: **Saira Imtiaz**Email: [saira.khan@pkli.org.pk](mailto:saira.khan@pkli.org.pk)**ABSTRACT**

An abnormality of the inferior vena cava—the retrocaval ureter—is an uncommon congenital disorder. In development, the ureter descends posteriorly to the inferior vena cava. Although it commonly affects patients in their paediatric years, people aged in their third and fourth decades of life have the highest likelihood to express symptoms like hydronephrosis which is usually in the end caused by ureteric blockage. As well as retrocaval ureters may have no symptoms at all, which may explain their being not frequently found globally or reported less widely. In this case, the male patient's medical record was surveyed by us and the resulting findings showed that a 21 year-old had a right-sided UPCO due to a right retrocaval ureter for the Ages. The double J stent was placed, and this problem treated clinically with a right pyeloplasty

**INTRODUCTION**

The circumcaval ureter, also called the retrocaval ureter, has been identified in less than 200 cases since it was first described in 1893 [1]. The proximal ureter inserts posteriorly into the renal pelvis and then into the inferior vena cava (IVC) as a result of this abnormality. The infrarenal IVC forms abnormally, ventrally of the subcardinal vein and hence ventrally of the ureter, from the vitellines vein suprarenal part (Figure 1). Normally, the infrarenal IVC is formed dorsally from supracardinal vein between fetal weeks four through eight [1]. The distal ureter commonly traverses superficially over the common iliac arteries before reaching the bladder [2]. Despite the fact that the abnormality is present from birth, some patients with IVC compression of their proximal ureter, resulting in hydronephrosis or hydroureteronephrosis, occasionally exhibit no symptoms until their third or fourth decade [3].

**Case Presentation**

The male patient in this instance, who was 21 years old, was seen in the urology outpatient department. He had been experiencing right flank pain for a month, but had no fever, hypertension, diabetes, or myelitis. His primary diagnosis was chronic obstructive

pyelonephritis. A year ago, he underwent a surgical procedure for stone passage. A retrocaval ureter with kinking at the level of the L-4 vertebra, along with an upstream hydro ureter and hydronephrosis, was observed on the right side of the abdomen and pelvis on computed tomography (CT) scans (Figure 1).

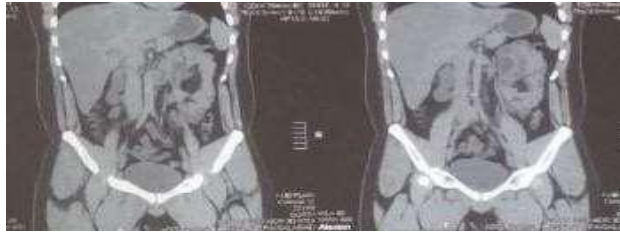**Authors Contribution**

**NBN.** Concept & Design of Study **AR** Drafting **NZ,SM.**Data Analysis **SI.** Critical Review **NBN.**Final Approval of version

**Citations:** Bin Nusrat, N., ur Rehman, A., Zafar, N., Muhammad, S., Imtiaz Bajwa, S., & Imtiaz, S. (2023). Hydroureteronephrosis Caused by a Retrocaval Ureter: A Rare Case Report. Pakistan Journal of Urology (PJU), 1(01), 26–29. <https://doi.org/10.69885/pju.v1i01.19>

Pak J Urology-Vol-01-Issue-01

Figure 1: Coronal computed tomography of the abdomen and pelvis showing a visible intravenous contrast-dilated ureter flowing beneath the inferior vena cava. (Fish-hook sign)



The patient had retrocaval ureter-related moderate hydronephrosis, although he showed no symptoms for a few years. But he came with right flank pain for one month. A renal scan showed adequate functioning of the left kidney was seen with no outflow obstruction, whereas the properly functioning right-

Sided kidney with sluggish clearance in response to diuretic stress (Figure 2).

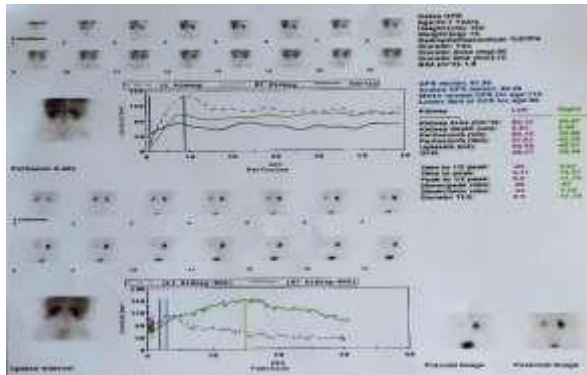


Figure 2: Diuretic renogram showing mild obstruction

Intravenous urogram (IVU) was also done to confirm dilated ureter was coursing behind IVC, showing a Fish-hook sign.

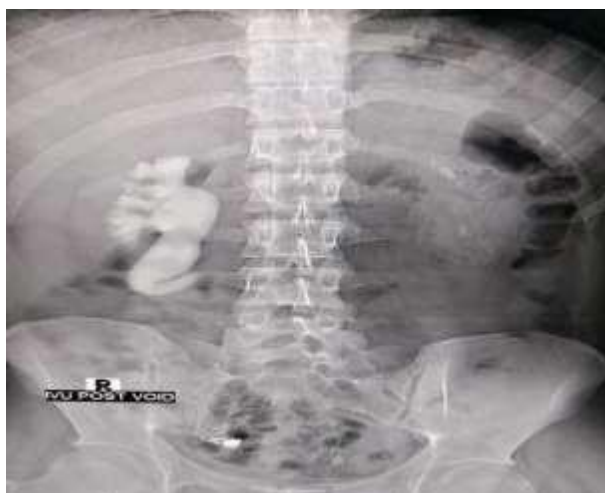

Figure 3: Intravenous urogram (IVU) showing Fish-hook shaped deformity

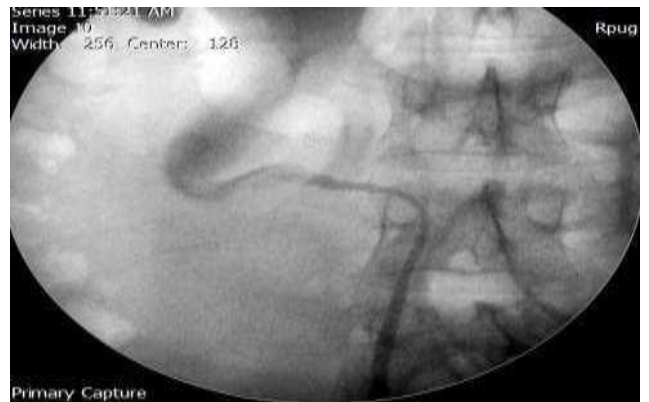
**Investigations**

Complete blood count (CBC), chemistry panel (CMP), liver, and renal function tests performed before surgery on the patient were generally unremarkable. However, table no. 1, in this case, presents some results from a renal scan.

Investigations	Values	Normal Range
Total GFR (Both Kidneys)	88 ml/min	90-120 ml/min
Left Kidney GFR	48 ml/min	60 or above ml/min
Right Kidney GFR	40 ml/min	60 or above ml/min
Differential function of Left Kidney	55%	Between 45% and 55%
Differential Role of Right Kidney	45%	Between 45% and 55%

**Management**

A retrograde uteropyelogram (RPUG) was done before pyeloplasty for further confirmation that showed the right ureter passing posterior to the inferior vena cava (retrocaval ureter) shown in Figure 4. Therefore, he was clinically managed for right Pelviureteric junction obstruction (PUJO) due to right retrocaval ureter via right pyeloplasty and double J stent for better management.



**Discussion**

Type one and type two retrocaval ureters can be separated into two groups. In type 1, the third lumbar vertebra is the level at which the ureter attaches posteriorly to the IVC—an S- or fish-hook-shaped malformation results from the moderate-to-severe hydronephrosis that causes it. In type two, which is less frequent, the proximal ureter travels posteriorly to the IVC at the same level as the renal pelvis, when it takes on a smooth sickle-shaped curvature [3-5]. Urine flow may be restricted as a result of ureteric, renal pelvic, and renal calyces enlargement. Severe circumstances may result in renal cortical atrophy [6]. The patient in our instance had a retrocaval ureter of type 1. Symptoms of obstructive uropathy include nephrolithiasis, recurrent UTIs, and soreness in the

right flank.

, and hematuria are commonly used to define the clinical look of symptomatic patients [7]. Chronic flank pain, typical laboratory results, as well as right-sided hydronephrosis found during CT: these are the medical characteristics of both patients from three previous reports. A indication of the severity of the hydronephrosis is not given; but excision of the retrocaval segment and end-to-end ureteral anastomosis were recommended in both case reports. The patient got right pelvic ureteral-junction "blockage"(PUJO) this time, & had right flank pain. Retrocaval ureter can be diagnosed by imaging in several ways. CT urography is the preferred method since it is the most accurate and least evasive way of interpreting the retrocaval ureter. Graphically, it shows the relationships between IVC and the ureter. A spiral CT scan can define the ureter and IVC, which according to some reports is better. No radiation risk or iodine damage is suffered by CT imaging and magnetic resonance imaging [9]. A renal nuclear scan can determine the extent of blockage. An ultrasound can show a kidney's pyelo-calyceal dilatation. In our instance, an intravenous urogram (IVU), a retrograde pyelogram, and computed tomography of the kidneys, ureters, and bladder (KUB) were used to diagnose a retrocaval ureter. Surgery is necessary for patients who are symptomatic and have severe hydronephrosis and failing kidney function, but it is not necessary for individuals who are asymptomatic and have mild to moderate hydronephrosis. [10]. In our situation, the patient had hydronephrosis symptoms brought on by a retrocaval ureter. Hydronephrosis can be graded in a variety of ways. The severity of renal pelvic dilatation is evaluated by the Society of Foetal Urology (SFU) as opposed to parenchymal loss, assessed by the radiology grading system. Although the most widely used, SFU is mainly employed to assess neonatal and infant pelvicaliectasis. By considering the renal parenchyma's quality and the dilatation of the pelvicalyceal system, the Onen grading method assesses renal impairment. The characteristics of this grading scheme are repeatable and standardized [11].

## Conclusions

In this instance, a retrocaval ureter observed on a CT scan has caused a rare type of clinically symptomatic hydronephrosis. Utilizing a CT scan represents the most effective preoperative diagnostic method. Asymptomatic patients should undergo conservative treatment, although minimally invasive laparoscopic surgery is the standard of care for rectifying this

abnormality. While retrocaval ureter is a rare anomaly, more cases are regularly reported. The root cause of this is likely multifaceted, possibly involving advancements in radiographic imaging, improved healthcare access, or an increase in physician reports. Nonetheless, whether there is a low or high index of suspicion for this condition, it is crucial to consider the retrocaval ureter in patients with symptomatic hydronephrosis.

## References

1. Atawurah H, Maison PO, Owusu-Ansah M, Asante-Asamani A: Retrocaval ureter: report of two cases. *Case Rep Urol.* 2019, 2019:2815748. 10.1155/2019/2815748
2. Lesma A, Bocciardi A, Rigatti P: Circumcaval ureter: embryology. *Eur Urol Suppl.* 2006, 5:444-8. 10.1016/j.eursup.2006.02.008
3. Kyei MY, Yeboah ED, Klufio GO, et al.: Retrocaval ureter: two case reports. *Ghana Med J.* 2011, 45:177-80.
4. Kenawi MM, Williams DI: Circumcaval ureter: a report of four cases in children with a literature review and a new classification. *Br J Urol.* 1976,48:183-92.10.1111/j.1464-10x.1976.tb10197.xBateson EM, Atkinson D: Circumcaval ureter: a new classification. *Clin Radiol.* 1969, 20:173-7. 10.1016/s0009-9260(69)80166-2
5. Iqbal S, Raiz I, Faiz I: Bilateral hydronephrosis with a hypertrophied, trabeculated urinary bladder. *Malays J Med Sci.* 2017, 24:106-15. 10.21315/mjms2017.24.2.14
6. De Arruda GJ, de Arruda Neto JF, Eroles JC, Spessoto LC, de Arruda JG, Fácio FN Jr: Incidental finding of the retrocaval ureter in a patient without hydronephrosis. *AME Case Rep*2018,2:42. 10.21037/acr.2018.09.01
7. Abdessater M, El Khoury R, Elias S, Bart S, Coloby P, Sleiman W: Diagnosis and laparoscopic management of retrocaval ureter: a review of the literature and our case series. *Int J Surg Case Rep.* 2019, 59:165-75. 10.1016/j.ijscr.2019.05.036
8. Feldman SL, DiMarco ER, Tencer T, Ross LS: Retrocaval ureter: radiographic techniques

directing surgical management. Br J Urol. 1982, 54:212-5. 10.1111/j.1464-410x.1982.tb06960.x



9. Matsuda T, Yasumoto R, Tsujino T: Laparoscopic treatment of a retrocaval ureter. Eur Urol. 1996,29:115-8. 10.1159/000473729
10. Onen A: Grading of hydronephrosis: an ongoing challenge. Front Pediatr. 2020, 8:458. 10.3389/fped.2020.00458

**Open Access** This article is licensed under a Creative Commons Attribution 4.0 International License, which permits use, sharing, adaptation, distribution and reproduction in any medium or format, as long as you give appropriate credit to the original author(s) and the source, provide a link to the Creative Commons license, and indicate if changes were made. The images or other third party material in this article are included in the article's Creative Commons license, unless indicated otherwise in a credit line to the material. If material is not included in the article's Creative Commons license and your intended use is not permitted by statutory regulation or exceeds the permitted use, you will need to obtain permission directly from the copyright holder. To view a copy of this license, visit: <http://creativecommons.org/licenses/by/4.0/>.  
© The Author(s) 2023